



DAISY BANK,
ROCHDALE.
October 16th 1930.

REPORT OF POST MORTEM EXAMINATION CARRIED OUT BY

DR. J.S.Pooley. AT The Rochdale mortuary ON Oct. 16th 1930.

NAME WILLIAM PENNINGTON. AGE 65 YEARS

ADDRESS

HISTORY Employed by Turner Bros. Asbestos Co. Ltd., from 2nd november 1913 to 18th April 1930.

EXTERNAL APPEARANCE Body of a grey haired old man, rather stout. Aedema of the legs especially the left.

SKELETON Evidence of old injury to right elbow.

HEAD

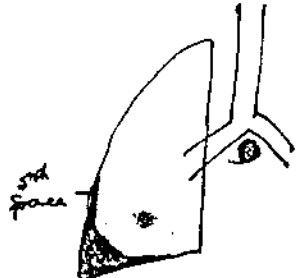
BRAIN Normal.

MENINGES Normal.

SKULL Normal.

AIR PASSAGES normal except for congestion of the mucous m membranes.

SPINAL CORD Not examined.



CHEST

RIGHT SIDE

Pleural Cavity Little fluid in central part. Seat of dense adhesions especially at base and to less extent at apex. Mid. portion free.

Lung Solid mass especially at costo phrenic angle extending up to fifth space. Malignant glands at bifurcation of trachea. All glands the seat of anthracosis. Lung tissue solid in consistence with a doubtful nodule of growth in middle of lower lobe.

LEFT SIDE

Pleural Cavity free. No fluids. No pleural thickening.

Lung Some naked eye evidence of asbestosis.

CHEST
Contd.

HEART

Pericardium Normal.

Muscle Secondary growth in anterior wall of left ventricle. 1 inch in diameter.

Valves slightly hardened.

Aorta Atheromatous patches above the valves but not obstructing the coronary artery. Abdominal aorta showed some atheroma.

Coronary Artery Not seriously diseased.

ABDOMEN

Some small amount of clear fluid.

LIVER Normal.

SPLEEN Rather large, otherwise normal.

STOMACH Distended.

INTESTINES Very much distended.

PANCREAS Normal, no growth.

KIDNEYS Right normal.
Left normal.

BLADDER Distended with urine.

~~TESTICLES~~

TESTICLES Normal.

CAUSE OF DEATH

CARCINOMA OF PLEURAS
SECONDARY GROWTHS IN HEART MUSCLE AND
MEDIASTINAL GLANDS.

